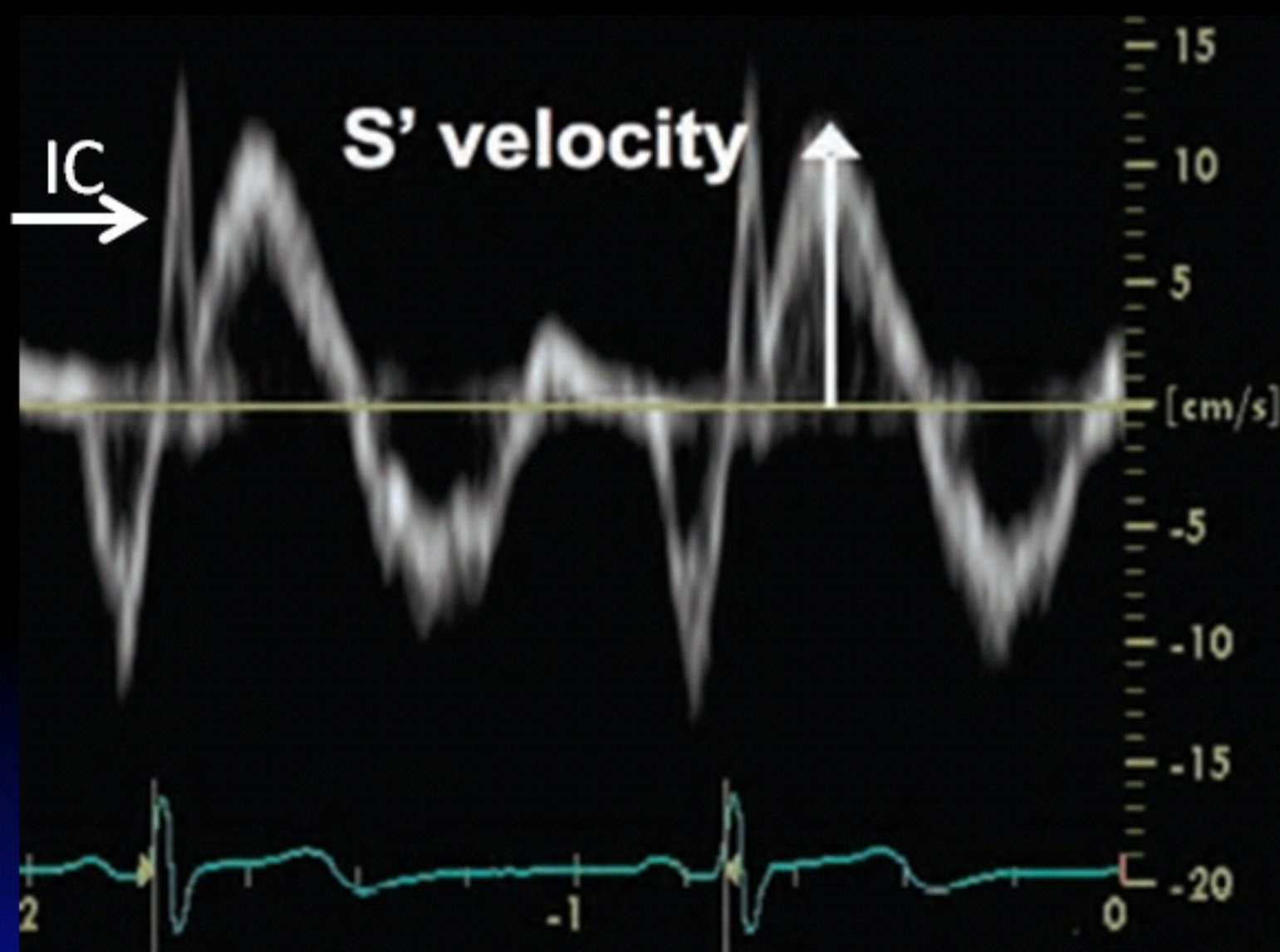


# Pulse Doppler “S” Wave

- TDI of the tricuspid annulus from the Apical view
- S' will be above the baseline
- Easy to perform and reproducible
- Angle Dependent
- Normal value >9.5cm
- Be sure not to measure the IC



IC = isovolumic contraction

