



National Basketball Association

Required Protocol for the Identification of Cardiovascular Disease

Frederick Basílico, MD; John DiFiori, MD; Mike Emery, MD; David Engel, MD;
N.A. Mark Estes, III, MD; Fred Feuerbach, MD; Shunichi Homma, MD; Jonathan Kim, MD;
Jimmie Mancell, MD; Barry Maron, MD; Matt Martinez, MD; Dermot Phelan, MD;
Howard Petroff, MD; Vera Rigolin, MD; Allan Schwartz, MD; David Shipon, MD; King Yee, MD

Cardiovascular screening is to be conducted in accordance with the scientific statement of the American Heart Association as set forth in “Recommendations and Considerations Related to Preparticipation Screening for Cardiovascular Abnormalities in Competitive Athletes: 2007 Update” (attached for reference). Accordingly, at a minimum, such screening must include:

Detailed Medical History

1. Assess for symptoms of exertional chest pain/discomfort
2. Assess for unexplained syncope or near-syncope
3. Assess for excessive/out of proportion shortness of breath with exercise
4. Ask if there has been any personal history of a heart murmur or high blood pressure
5. Take a detailed personal medical history with particular emphasis on cardiac illnesses that could potentially cause injury to young athletes (AHA recommendations attached as a guideline reference)¹

Physical Exam

1. Assess for the presence of a heart murmur
2. Assess femoral pulses to exclude aortic coarctation
3. Assess for physical stigmata of Marfan Syndrome
4. Brachial artery blood pressure in the sitting position

Objective Data

1. Standard 12 lead electrocardiogram. Refer to the “International Criteria” reference on normal and abnormal ECG findings in athletes² (attached as a guideline reference)
2. Follow NBA protocols for two-dimensional echocardiogram with Doppler and stress for players who have not previously completed the NBA stress echocardiogram (attached)
3. Interpretation: Consider against guideline for echocardiogram and Echocardiographic Screening Guidelines for Professional Basketball Players (attached as a guideline reference)

Lipid Panel/Blood Glucose

1. Test to include total cholesterol, LDL, HDL, triglycerides
2. Interpretation: Abnormal values justify further consideration and evaluation in context of coronary artery disease and risk factors

¹ (1) Maron BJ, Friedman RA, Kligfield P et al.; on behalf of the American Heart Association Council on Clinical Cardiology et al. Assessment of the 12-lead ECG as a screening test for detection of cardiovascular disease in healthy general populations of young people (12–25 years of age): a scientific statement from the American Heart Association and the American College of Cardiology. *Circulation*. 2014;130:1303–1334.; (2) Chandra N, Bastiaenen R, Papadakis M, Sharma S. Sudden Cardiac Death in Young Athletes: Practical Challenges and Diagnostic Dilemmas. *J Am Coll Cardiol*. 2013;61(10):1027-1040. Doi:10.1016/j.jacc.2012.08.1032.

² Sharma S, Drezner JA, Baggish A et al. International Recommendations for Electrocardiographic Interpretation in Athletes. *J Am Coll Cardiol*. 2017; 69(8): 1057-1075

Table 1. The 14-Element AHA Recommendations for Preparticipation Cardiovascular Screening of Competitive Athletes

Medical history*

Personal history

1. Chest pain/discomfort/tightness/pressure related to exertion
2. Unexplained syncope/near-syncope†
3. Excessive and unexplained dyspnea/fatigue or palpitations, associated with exercise
4. Prior recognition of a heart murmur
5. Elevated systemic blood pressure
6. Prior restriction from participation in sports
7. Prior testing for the heart, ordered by a physician

Family history

8. Premature death (sudden and unexpected, or otherwise) before 50 y of age attributable to heart disease in ≥ 1 relative
9. Disability from heart disease in close relative < 50 y of age
10. Hypertrophic or dilated cardiomyopathy, long-QT syndrome, or other ion channelopathies, Marfan syndrome, or clinically significant arrhythmias; specific knowledge of genetic cardiac conditions in family members

Physical examination

11. Heart murmur‡
12. Femoral pulses to exclude aortic coarctation
13. Physical stigmata of Marfan syndrome
14. Brachial artery blood pressure (sitting position)§

AHA indicates American Heart Association.

*Parental verification is recommended for high school and middle school athletes.

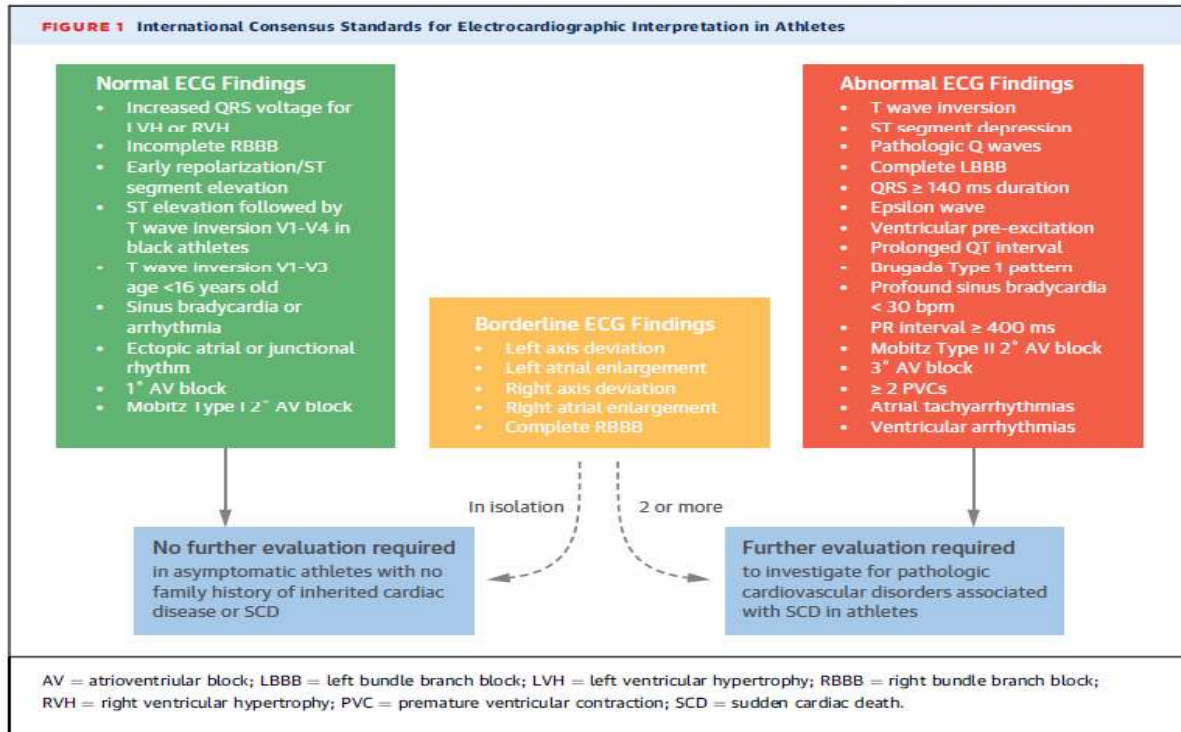
†Judged not to be of neurocardiogenic (vasovagal) origin; of particular concern when occurring during or after physical exertion.

‡Refers to heart murmurs judged likely to be organic and unlikely to be innocent; auscultation should be performed with the patient in both the supine and standing positions (or with Valsalva maneuver), specifically to identify murmurs of dynamic left ventricular outflow tract obstruction.

§Preferably taken in both arms.

Modified with permission from Maron et al.³ Copyright © 2007, American Heart Association, Inc.

Electrocardiographic Interpretation in Athletes: the International Recommendations[§]



Definitions

ECG finding

Left atrial enlargement
 Right atrial enlargement
 Left axis deviation
 Right axis deviation
 Right ventricular hypertrophy
 ST depression
 Pathologic Q waves
 Ventricular pre-excitation
 T wave inversions

Definition

Negative portion of P wave in V1 ≥ 1 mm in depth and ≥ 40 ms in duration
 P wave amplitude ≥ 2.5 mm in leads II, III, or aVF
 -30° to -90°
 $>115^\circ$
 Sum of R wave in V1 + S wave in V5 or V6 ≥ 10.5 mm
 ≥ 0.5 mm deep in 2 or more leads
 Q/R ratio ≥ 0.25 or ≥ 40 ms in duration (excluding II and aVR)
 PR interval < 120 ms with delta wave
 ≥ 1 mm in depth in 2 or more leads (excludes III, aVR, V1)

***For players with T wave inversions (TWI) affecting the lateral leads (I, aVL, V5 and/or V6) further evaluation with cardiac MRI with gadolinium is required** (asymptomatic players with no family history of inherited cardiac disease or SCD and no abnormal testing other than the TWI, do not need to be withheld from basketball activities prior to completing the cardiac MRI). For players with lateral TWI and upper limits of LV wall thickness (13-15 mm) Holter monitoring should be considered. Players with lateral TWI should be evaluated on a prioritized basis on annual preseason cardiac examinations.

[§] Sharma S, Drezner JA, Baggish A et al. International Recommendations for Electrocardiographic Interpretation in Athletes. *J Am Coll Cardiol.* 2017; 69(8): 1057-1075

NBA Screening Protocol: Two-Dimensional Echocardiogram with Doppler

This protocol document describes the NBA requirements for an echocardiogram screening examination for an NBA player.

General Requirements

- Record name, height and weight, DOB
- Measure blood pressure
- **Echocardiogram Report:** Within three days of completing the examination, must upload to the NBA electronic medical records system (the NBA “EMR”) the complete final echocardiogram report (no summaries)
- **Cardiac Imaging:** Within three days of completing the examination, must upload to the NBA EMR the full set of echocardiogram images obtained during the screening; all files must be DICOM type and may not be .avi, .wmv, or other similar video files
- **Ambra “Gateways”:** To promote efficient upload of imaging studies and reports, and to avoid the need for manual uploads by team staff and/or consulting medical personnel, teams are strongly encouraged to establish digital “gateways” between Ambra Health (the EMR’s integrated, cloud-based imaging platform) and any cardiology/medical affiliate(s) utilized by the team. (For questions about Ambra, or to establish a new gateway with an affiliated cardiology/medical center, please contact Davis Bitton (davis.bitton@intelerad.com, 208-713-7010) or the league office.)
- NOTE: Teams or their medical personnel are not required to make strain calculations

Please note that in addition to the requirements in this document:

1. The sonographer performing the echocardiogram may – and in certain cases should (e.g., to further evaluate the structure and function of a valve) – supplement the required views and measurements noted below with any additional views and/or measurements that they deem appropriate based on findings during the screening examination or that are additionally required at the medical center at which the echocardiogram is performed.
2. Based on findings from a player’s screening examination, a team physician (which, for clarity, for this purpose, can include the team consulting cardiologist), in their clinical judgment (or at the direction of the NBA), also may determine that it would be medically appropriate to obtain additional views and/or measurements or for the player to undergo additional cardiac evaluation.

All measurements and findings, including that are obtained in addition to the requirements in this document, must be recorded in the team consulting cardiologist’s final echocardiogram report.

Parasternal Views

1. 2D PLAX (ALL CLIPS to be ≥ 2 beats)
2. PLAX measurements:
 - a. LV (diastolic and systolic measurements)
 - b. LV wall thickness
 - c. LA diameter (optional if LA volume can be measured and is recorded)
 - d. Aortic root/sinus of Valsalva (obtain an additional 2D PLAX of aortic root if > 4 cm at root)
3. 2D PLAX of ascending aorta (move up an intercostal space)
 - a. Additional 2D PLAX of ascending aorta if > 4 cm
4. PLAX with color box around both mitral and aortic valves (aliasing velocity 50-70 cm/sec)
 - a. If $>$ mild MR, measure vena contracta
5. Tricuspid valve inflow view
6. Tricuspid valve inflow view with color flow (aliasing velocity 50-70 cm/sec)
7. Measure TR jet velocity for RVSP if there is sufficient TR
8. Pulmonic valve outflow view (and image PA bifurcation if visible)
9. Pulmonic valve outflow CW

10. Pulmonic valve outflow view with color flow (aliasing velocity 50-70 cm/sec)
11. 2D PSAX at level of base of heart showing leaflets of AV in short axis
12. 2D PSAX at level of base of heart with color box on aortic valve
13. 2D PSAX at level of mitral valve
14. 2D PSAX level of papillary muscle
15. 2D PSAX at apical level

Apical Views

1. 2D Apical 4 chamber view:
 - a. LV volumes and EF (use Simpson's biplane), LA volume (biplane)
 - b. 2D Apical 4 chamber view with color box on MV (aliasing velocity 50-70 cm/sec)
 - i. If > mild MR, record PISA measurements (measure in apical view where PISA is best seen)
 - c. PW of MV at leaflet tips (measure and record peak E, Peak A)
 - d. Tissue Doppler at lateral and medial annulus (measure and record both e' and E/e')
 - e. Tissue Doppler of the Tricuspid annulus (measure and record s')
 - f. Measure and record TAPSE using M-mode
 - g. Apical 4 chamber view with color box on TV (aliasing velocity 50-70 cm/sec)
 - i. Measure and record TR jet velocity for RVSP if there is sufficient TR
2. 2D Apical 5 chamber view:
 - a. Apical 5 chamber view with color box on AV (aliasing velocity 50-70 cm/sec)
 - b. PW at LV outflow tract
 - c. CW of AV
 - d. Pressure $\frac{1}{2}$ time of AR if AR > mild
3. 2D Apical 2 chamber view:
 - a. Apical 2 chamber view measurements:
 - i. Measure LV volume and EF (using biplane Simpson's)
 - ii. Measure LA volume (using biplane)
 - b. Apical 2 chamber view with color box on MV
4. 2D apical 3 chamber view:
 - a. Obtain 3 chamber view
 - b. Apical 3 chamber view with color box on MV and AV
 - i. If > mild MR, record PISA measurements (measure in apical view where PISA is best seen)
 - c. PW of aortic outflow tract (if not obtained on 5 chamber view)
 - d. CW of aortic outflow tract (if not obtained on 5 chamber view)
 - e. Pressure $\frac{1}{2}$ time of AR if AR > mild

Subcostal Views

1. 4 chamber view
2. Additional short axis view of LV if PLAX views not adequate
3. IVC with sniff to measure RA pressure
4. Color Doppler across the interatrial septum to exclude an interatrial shunt (ASD, PFO)

Suprasternal Notch Views

1. View of aortic arch in long axis view
2. Color flow view of aortic arch

NBA Protocol: Stress Echocardiogram

General requirements

- Upload study (all images obtained during the test) and study report to NBA's electronic medical records system; all files must be DICOM type and may not be .avi, .wmv or other similar video file

Pre-exercise

- Resting vital signs data obtained, printed, and reviewed prior to exercise:
 - o Supine blood pressure
 - o 12 lead EKG (with standard modified stress lead placement)
- Echocardiographic imaging sequence:
 - o Ensure that back up imaging is acquired and saved
 - o Maximize 2-D 4 Chamber view, optimize and acquire images
 - o Rotate transducer to Apical 2 Chamber view, optimize and acquire images
 - o Maximize 2-D Parasternal Long Axis view, optimize and acquire images
 - o Rotate to Parasternal Short Axis view, optimize and acquire images
 - o Review the stored baseline images for quality, reproducibility, and any regional wall motion abnormalities
 - o Explain thoroughly post image acquisition "breath hold"; instructions to the patient
 - o Demonstrate and have patient practice post-exercise transition from treadmill to scanning bed for understanding, safety, and compliance
 - o If significant EKG or echocardiographic findings are noted with baseline acquired data, consult with the physician(s) for direction before proceeding with the stress portion (unless physician is performing the test)

Exercise phase EKG and blood pressure data

- The Bruce protocol (3 min stages) will be utilized during the exercise phase
- Blood pressure and 12 lead EKG will be obtained, printed, and reviewed at the following intervals:
 - o At beginning of test, standing
 - o Blood pressure obtained during the 3rd minute of each stage
 - o 12 lead EKG obtained every minute of exercise
 - o Blood pressure and EKG will be obtained anytime throughout the exercise phase if/when clinically warranted
 - o Peak exercise when heart rate is at or above target
- All arrhythmias will be recorded, printed, reviewed, and monitored throughout the exercise phase

Peak exercise images

- Peak images are obtained at any of the following scenarios:
 - o Unable to continue exercising due to fatigue, dyspnea, or other symptoms
 - o The target heart rate is achieved
 - o Significant EKG changes occur
 - o Hypertensive or hypotensive blood pressure response occurs
 - o Progressively worsening chest pain
 - o Any other significant symptoms

- Once the treadmill is brought to a complete stop, re-orient the patient on a rapid/safe transition back to the scanning bed
- Imaging sequence
 - o Turn on the SVHS recording so that there is imaging back up on VHS tapes
 - o Optimize 2-D 4 Chamber view and acquire images
 - o Optimize 2-D 2 Chamber view and acquire images
 - o Optimize 2-D Parasternal Long Axis view and acquire images
 - o Optimize 2-D Parasternal Short Axis view and acquire images
 - o Repeat imaging sequence if deemed necessary or when heart rate is still above target
- Review and select the best post-exercise stress images
- Review and side-by-side compare Rest and Post-exercise images

Recovery phase EKG and blood pressure data

- 12 lead EKG will be obtained, recorded, and printed at the following intervals:
 - o 1 minute post exercise
 - o 2 minutes post exercise
 - o 3 minutes post exercise
 - o 4 minutes post exercise
 - o 5 minutes post exercise
 - o At any point when clinically warranted
- Blood pressure will be measured and documented at the following intervals
 - o 1 minute post exercise
 - o 3 minutes post exercise
 - o 5 minutes post exercise
 - o At any point when clinically warranted
- When symptoms exist, blood pressure and EKG data will be collected and documented at the following intervals
 - o At the point in time when symptoms subside
 - o EKG changes return to baseline
 - o Echocardiographic changes return to baseline

If EKG changes, ischemic symptoms, hypo/hypertensive response, or echocardiographic wall motion abnormality is present at rest or with exercise, recovery echocardiographic images need to be obtained.

Study Conclusion

- Disconnect 12 lead EKG electrodes from the patient
- Provide towel or hand towel to the patient for removal of any remaining AquaSonic Gel

Scenarios to consult with the physician(s) once the stress echo is completed (unless physician is performing the test)

- Symptoms during and after exercise
- Abnormal EKG or blood pressure response to exercise
- Newly identified wall motion abnormality before/after exercise
- Abnormal hemodynamic response

Thresholds for Required Notification to League Office
Following Echocardiographic and ECG Screening of Professional Basketball Players

Echo Thresholds for Required Notification	ECG Thresholds for Required Notification
LVEDD (mm) ≥ 71	WPW (Pre-Excitation)
Max LV Wall Thickness (mm) ≥ 15	Any IVCD with QRS > 140 msec
LVEF (%) ≤ 49	LBBB
Aortic Root Diameter (mm) ≥ 44	QTc > 500 msec
Valve regurgitation ≥ moderate	T wave inversions lateral leads (I,aVL,V5,V6)
Valve stenosis > mild	

If a player meets any of the thresholds noted above:

- Medical team physician and/or team consulting cardiologist must immediately email NBA league office (attn: Miheer Mhatre, mmhatre@nba.com or David Weiss, dweiss@nba.com)
- Medical team physician and/or team consulting cardiologist, must review echo/ECG and clinical data with Columbia, and if necessary, other specialists (including to determine any additional views and/or measurements that should be obtained and/or any additional evaluation that should be conducted) and discuss findings with player

Columbia cardiac consultants are available to teams at any time to discuss clinical cardiac data.

Please contact:

- David Engel – 212-326-8920 (o) | de165@cumc.columbia.edu | 914-629-7324 (m)

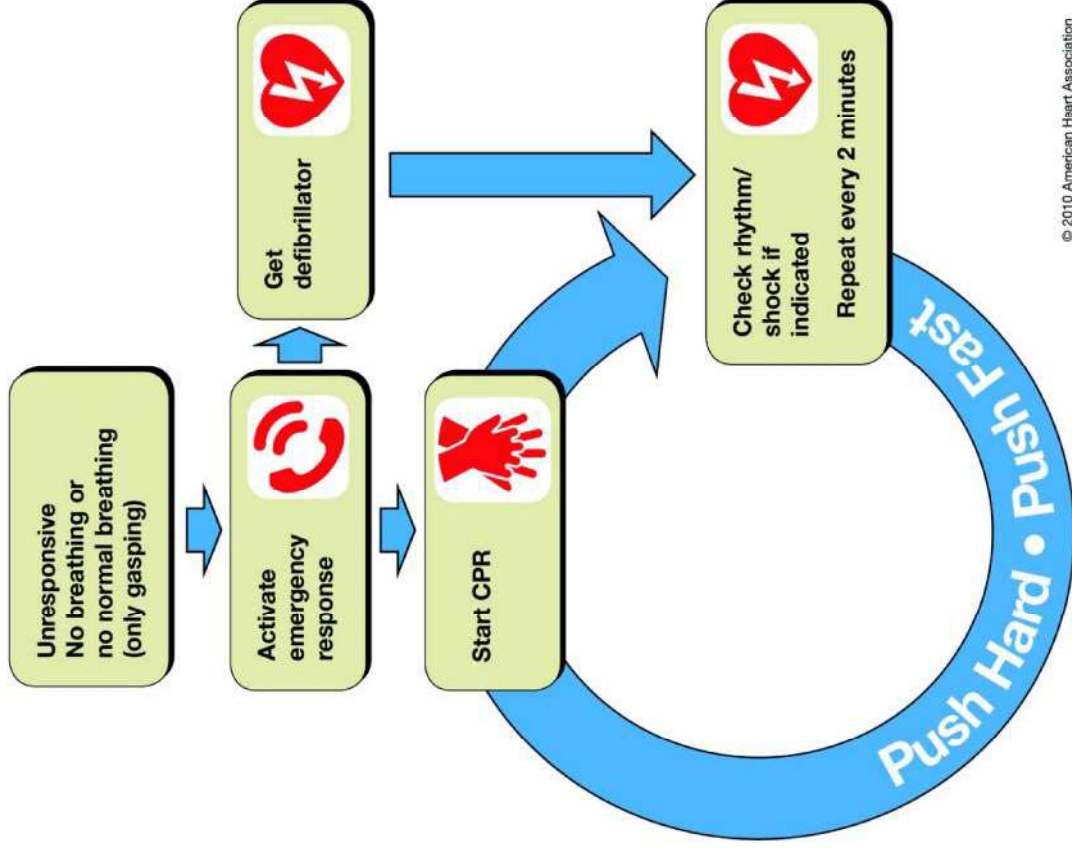
Or if Dr. Engel is unavailable:

- Allan Schwartz – 212-305-5367 (o) | as20@cumc.columbia.edu | 646-240-9535 (m)

Adult Basic Life Support Protocol

Simplified adult BLS algorithm.

Simplified Adult BLS



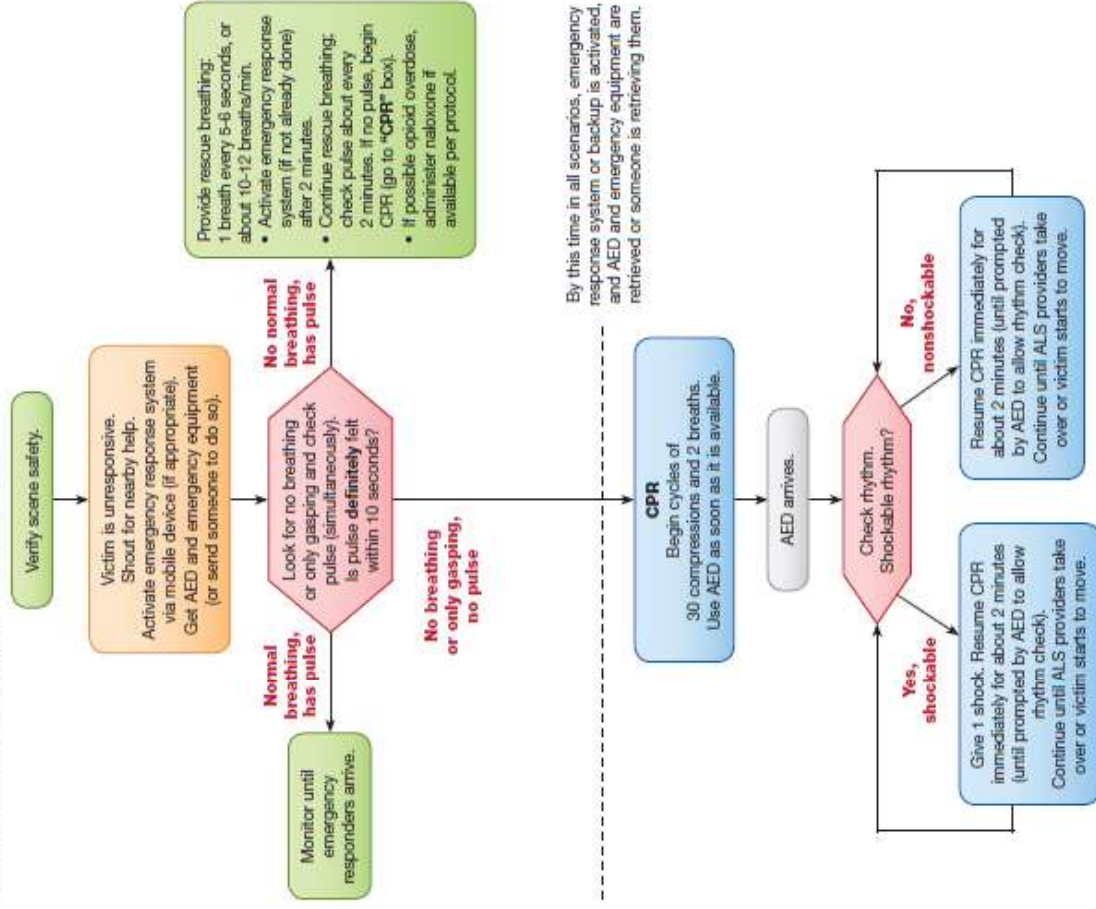
© 2010 American Heart Association

Robert A. Berg et al. Circulation. 2010;122:S685-S705



BLS healthcare provider algorithm.

BLS Healthcare Provider Adult Cardiac Arrest Algorithm – 2015 Update



© 2015 American Heart Association

Figure 1. BLS Healthcare Provider Adult Cardiac Arrest Algorithm—2015 Update.

Monica E. Kleinman et al. Circulation. 2015;132(suppl 2):S414–S435.





NBA Marfan Syndrome Focused Examination

Name: _____ DOB: _____

If potential incidence of Marfan Syndrome is suspected based on the results of the NBA Cardiovascular Screening Medical History Questionnaire, and the player has not previously undergone the NBA Marfan Syndrome Focused Examination, the physician must evaluate the player for the criteria below and discuss the results with the Columbia University cardiac consultants designated at the bottom of this form. The physician and player are not required to review or complete this focused examination if the player has previously completed it.

A. Marfan Criteria §

- | | | |
|---|------------------------------|-----------------------------|
| Wrist AND/OR Thumb Sign ¹ | <input type="checkbox"/> Yes | <input type="checkbox"/> No |
| Pectus Carinatum or Excavatum Deformity | <input type="checkbox"/> Yes | <input type="checkbox"/> No |
| Scoliosis or Thoracolumbar Kyphosis | <input type="checkbox"/> Yes | <input type="checkbox"/> No |
| Reduced Elbow Extension | <input type="checkbox"/> Yes | <input type="checkbox"/> No |
| Skin Striae | <input type="checkbox"/> Yes | <input type="checkbox"/> No |
| Hindfoot Deformity | <input type="checkbox"/> Yes | <input type="checkbox"/> No |
| Plain Flat Foot | <input type="checkbox"/> Yes | <input type="checkbox"/> No |
| Facial Features ² | <input type="checkbox"/> Yes | <input type="checkbox"/> No |
| Severe Myopia (>3 diopters) | <input type="checkbox"/> Yes | <input type="checkbox"/> No |
| Spontaneous Pneumothorax | <input type="checkbox"/> Yes | <input type="checkbox"/> No |

B. Additional Medical Notes by Physician (if needed)

Following this focused examination, the physician must discuss the results of this evaluation with a Columbia University cardiac consultant: attn. David Engel – 212-326-8920 (o) | de165@cumc.columbia.edu | 914-629-7324 (m); or if Dr. Engel is unavailable: Allan Schwartz – 212-305-5367 (o) | as20@cumc.columbia.edu | 646-240-9535 (m).

§ Loeys BL, Dietz HC, Braverman AC, et al; The revised Ghent nosology for the Marfan Syndrome. J Med Genet. 2010 Jul;47(7):476-85. Doi: 10.1136/jmg.2009.072785

¹ Please be advised that the thumb sign is positive when the entire distal phalanx of the adducted thumb extends beyond the ulnar border of the palm with or without the assistance of the patient or examiner to achieve maximal adduction. The wrist sign is positive when the tip of the thumb covers the entire fingernail of the fifth finger when wrapped around the contralateral wrist.

² The physician should evaluate the player for these typical facial characteristics: dolichocephaly (disproportionately long and narrow head); downward slanting palpebral fissures (slanting of space between eyelids); enophthalmos (recession of eyeball within orbit); retrognathia (recession of either or both jaws); and malar hypoplasia (underdeveloped cheekbones).